ESD for Esophageal Cancer

Dr Mohammad Bagheri, DDRI, TUMS

- The role of ESD in SCC of the esophagus is well established.
- ESD en bloc resection rates of 100% with local recurrence of 1% have been reported compared to 53 and 10%, respectively, for EMR.
- Involvement of muscularis mucosa with carcinoma increases the risk of lymph node metastasis to about 10%, and these patients will have higher recurrence rates if treated with ESD.
- Suggested indications for ESD for SCC ***includes T1a lesions limited to lamina propria***.
- Once the lesion invades the muscularis mucosa and infiltrates the superficial submucosa (up to 200 microm), the risk of local lymph node metastasis ***approaches 15%***, and these patients represent a relative indication for ESD after the evaluation for local lymph nodes.

Classifications of mucosal layer depth for the purposes of invasion and management

-Mucosa

- m1 epithelium
- m2 lamina propria
- m3 muscularis mucosa

-Submucosa

- Sm1 superficial

  Esophagus squamous cell 200 lm

  Esophagus Barrett's 500 lm

  Stomach 500 lm

  Colon 1000 lm

- Sm2 deep

Indications for ESD In Esophagus

- SCC Well/moderately differentiated <20 mm
- M1 or M2 cancers
- Absent venous and lymphatic Invasion
- Barrett's esophagus <20 mm HGD or IMC

- Patients with ***HGD and intramucosal cancer in the setting of Barrett's*** esophagus are candidates for ESD.
- Another indication for ESD is ***early adenocarcinoma lesions*** that are well differentiated, with ***less than 500-lm extension into the submucosa***.
- Studies demonstrate 90% en bloc resection rates with lower R0 resection rates but with over 95% long-term cure rates .
- When ESD is performed in the setting of Barrett's esophagus, it should be followed by ***radiofrequency ablation of any remaining Barrett's epithelium***.
- Based on a systematic review demonstrating a 1–2% lymph node metastasis in setting of intramucosal cancer in Barrett's, these patients are candidates for ESD given the mortality of ***1-2% associated with esophagectomy***.

Instruments

(a)



(b)



(c)



(d)





Electrosurgical units

- ***ENDO CUT® Q:*** This waveform is intended for applications where rapid cutting with reproducible tissue effect is paramount. It is used for mucosal incision as well as fine cutting in submucosa where hemostasis is not an issue. It also works to sculpt fibrotic tissue off muscularis propria.
- Typical setting used in these advanced procedures are ENDO CUT® Q Effect 3, cutting duration of 1 (amount of time spark is on for 1 ms), interval phase of 1 (length of time for soft coag phase).

DRY CUT:

- This waveform provides more hemostasis during cutting than ENDOCUT®Q due to increased voltage. This mode is used in areas where smaller capillaries are weeping into the dissection plane.
- It is useful when precise dissection with increased concurrent hemostasis (relative to ENDO CUT® Q) is needed such as well-vascularized submucosa during dissection.
- DRY CUT uses between 600 and 800 V, depending on the effect mode. If DRY is used, it is best to set a higher upper limit of wattage—some experts use upwards of 110 W (Effect 2), and others will routinely go to 180 W (Effect 4) in stomach.
- DRY CUT is also used for mucosal incision when oozing is continuous during peripheral incision, but the downside is increased thermal insult (which can be caused by a cutting delay).
- Therefore, it is important to keep a wider margin from the lesion to protect the specimen's margins for pathologic readability. The salient points here are as follows: ***(1) Set higher power limit to allow cutting without delay (different for every patient and electrode/knife)***, and ***(2) increase Effect up to 4 to increase hemostasis***.

FORCED COAG:

- This waveform is utilized for pinpoint coagulation, 880–1100 V depending on Effect 1 or Effect 2.
- It is also used with the side of the knife (increased surface area to drive more current) to pretreat larger vessels, devitalize them, and then transect.
- Consider injection around the vessel to tamponade and buffer surrounding structures prior coagulation being applied.
- Typical settings range from Effect 1 to Effect 2 (higher effect = higher voltage/thermal effect) and 25–50 W max.

SOFT COAG:

- This low-voltage (<200 V) coagulation waveform is used for marking around lesion for limited depth of penetration.
- The same waveform is used with hot coagulation graspers for vessel hemostasis.
- Grasp the vessel with tip of grasping forceps, tent away from the muscularis propria, and then cauterize until blanching and bubbling of target tissue is accomplished.
- A typical setting in Soft Coag would be Effect 5/80 W max.

SWIFT COAG

- This waveform can be used for submucosal dissection and is a bit more hemostatic with less cutting ability than DRY CUT.
- It can be used like FORCED COAG for pinpoint hemostasis of vessels during submucosal dissection but can sometimes cut, which can be undesirable (premature transection through vessel).
- SWIFT COAG is slightly less hemostatic than FORCED COAG.

Marking

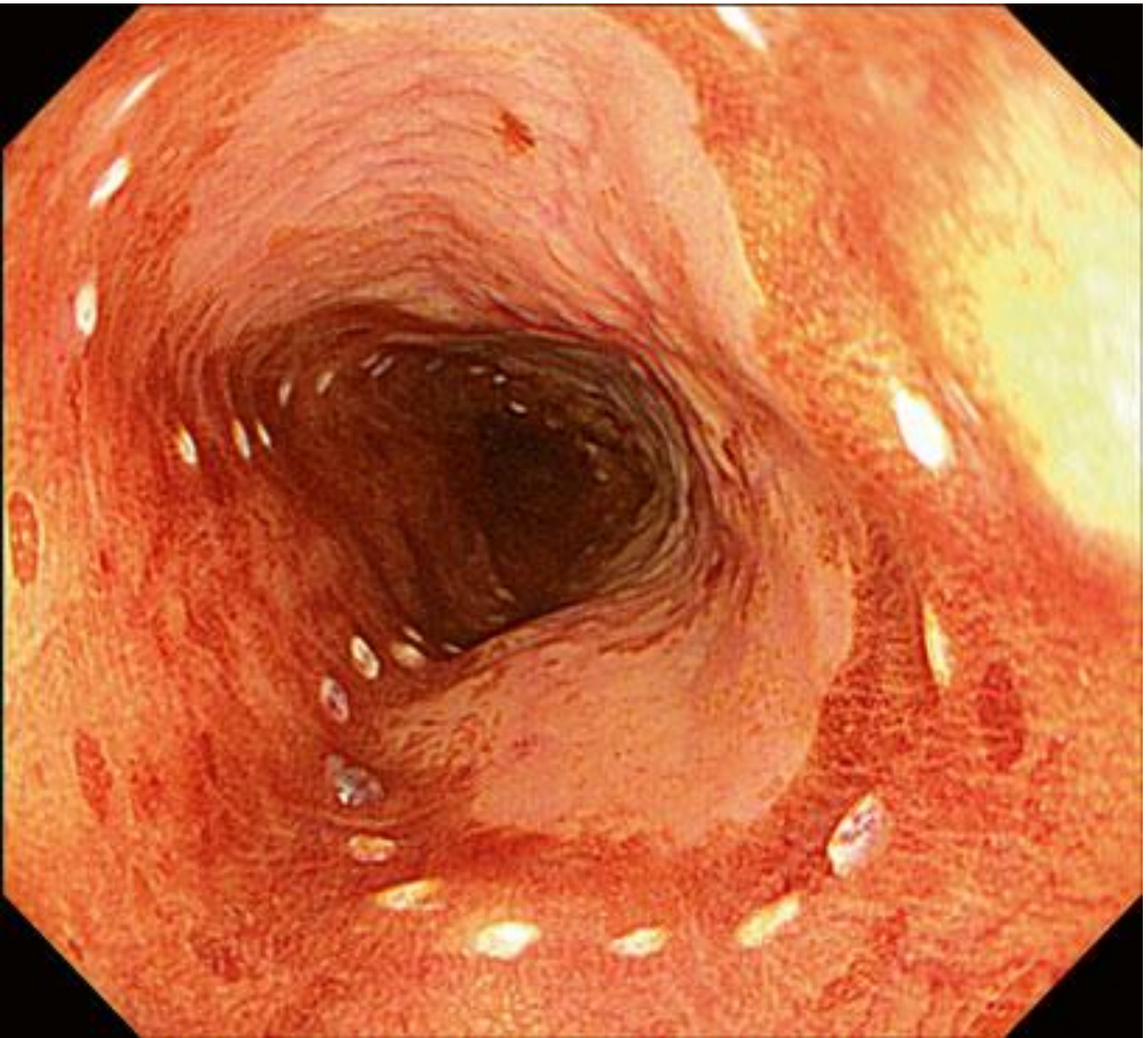

- The tip of the ESD knife is retracted within the sheath, and a mark is placed when the tip of the knife comes into contact with the mucosa

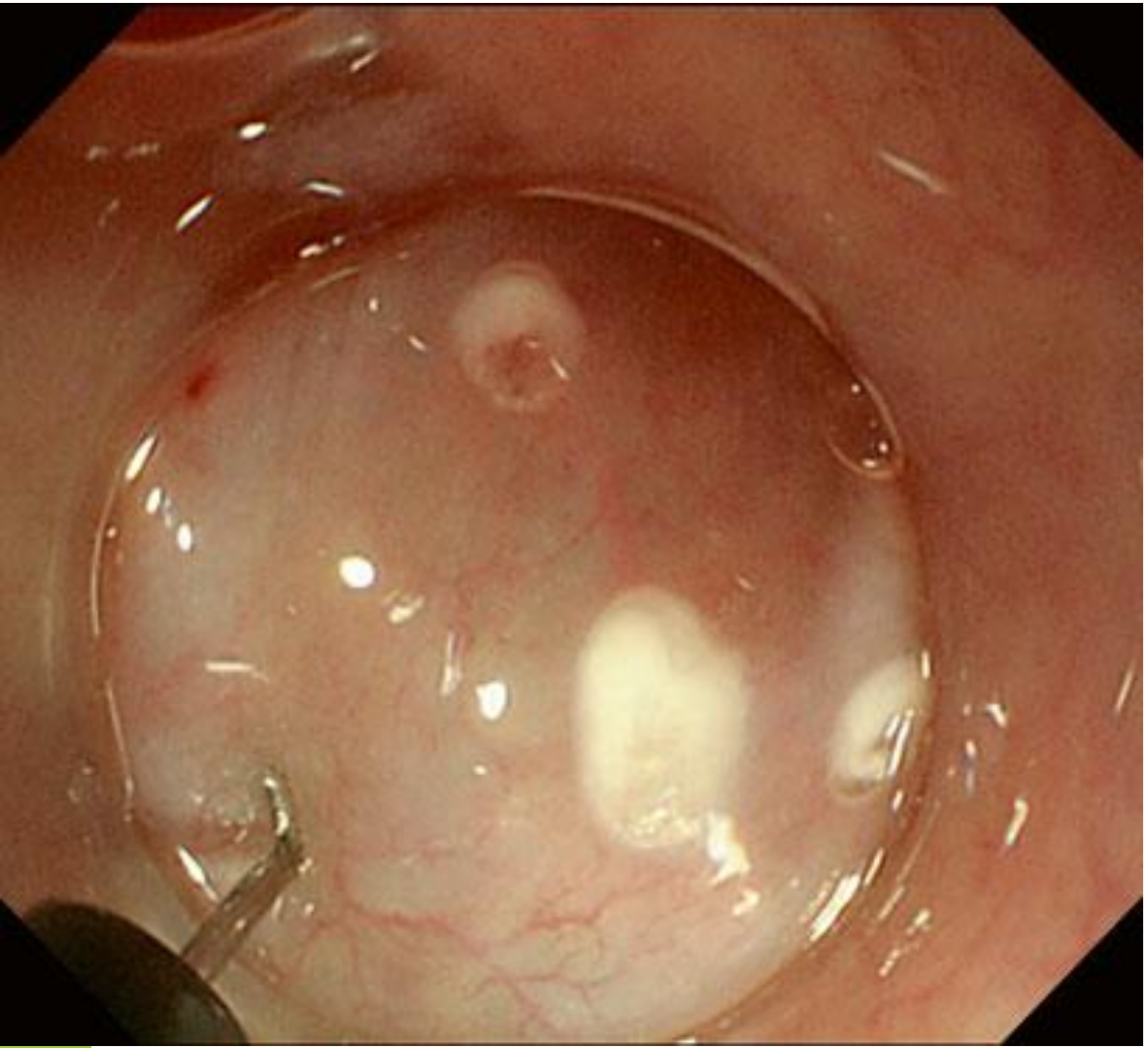

- The back side of the Hook Knife is placed so as to make contact with the mucosa, after submucosal injection of the fluid cushion, and a mucosal defect is made using the Endocut I mode

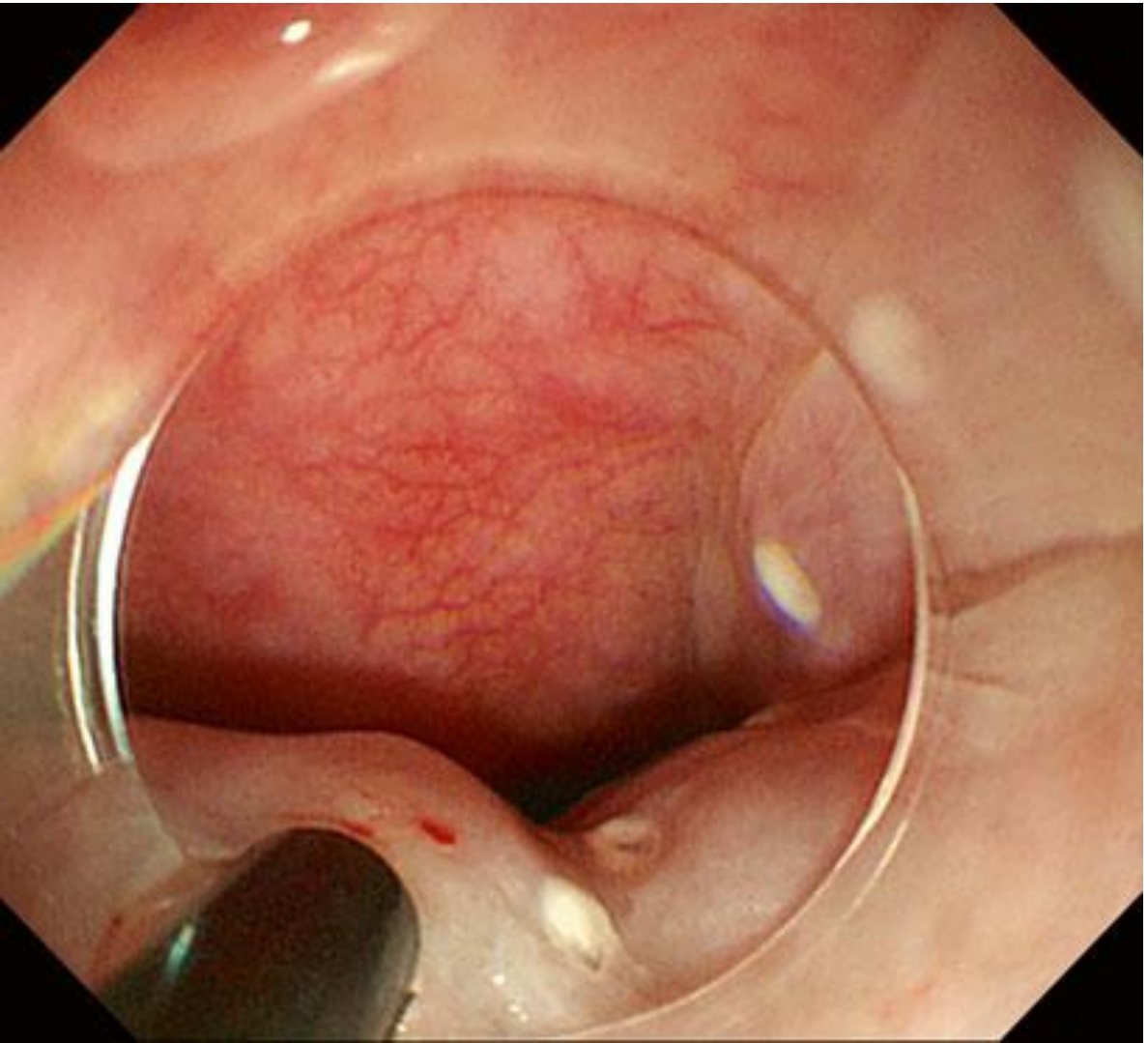

- The Hook Knife’s arm is used for vertical mucosal incision.
- The knife is directed toward the lumen and then inserted into the submucosal.
- The mucosa is then elevated toward the lumen with the knife’s arm, and then the mucosa is cut

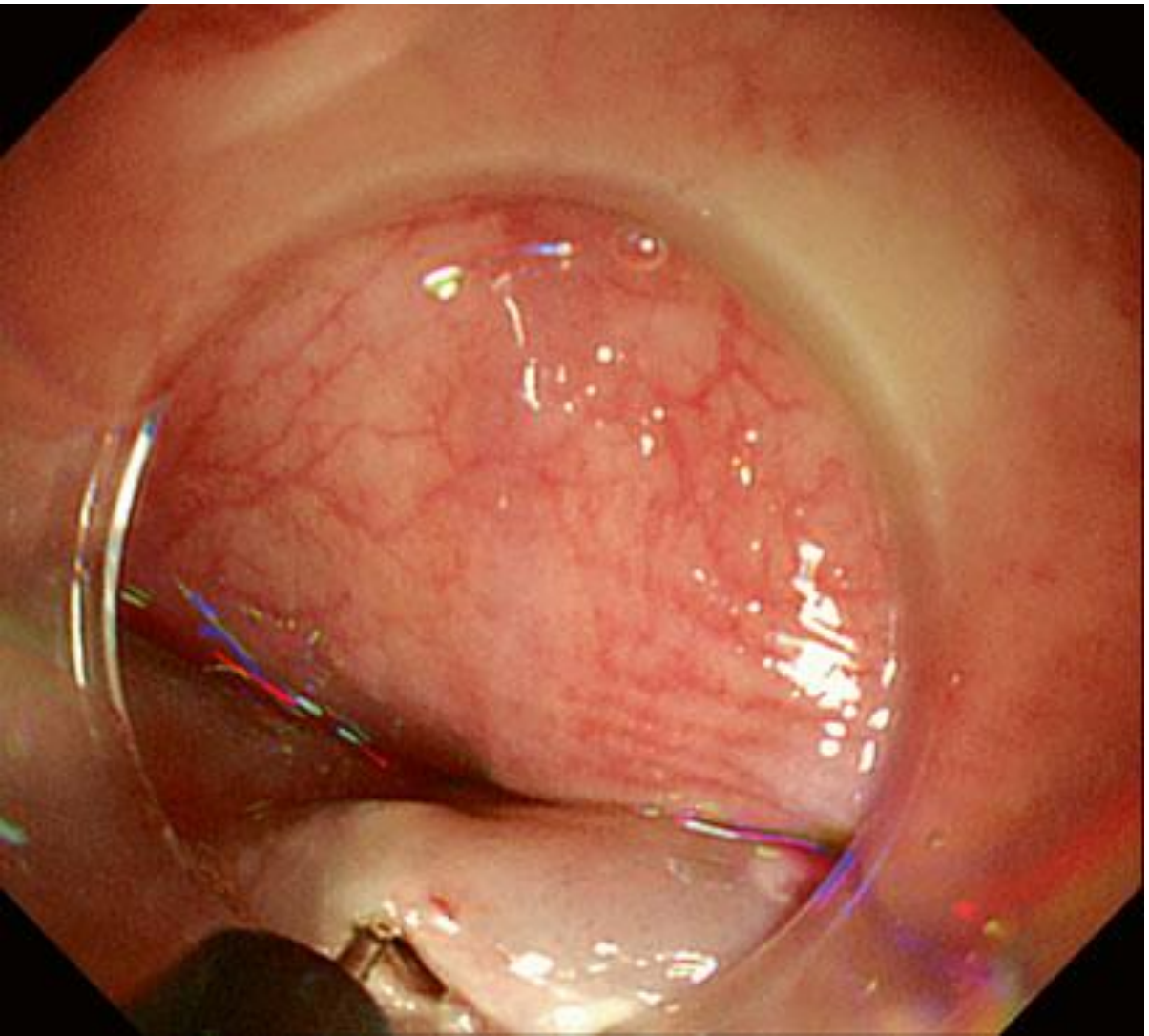

- The tip of the Hook Knife is inserted into the submucosal layer. The knife is used to hook and cut the mucosa

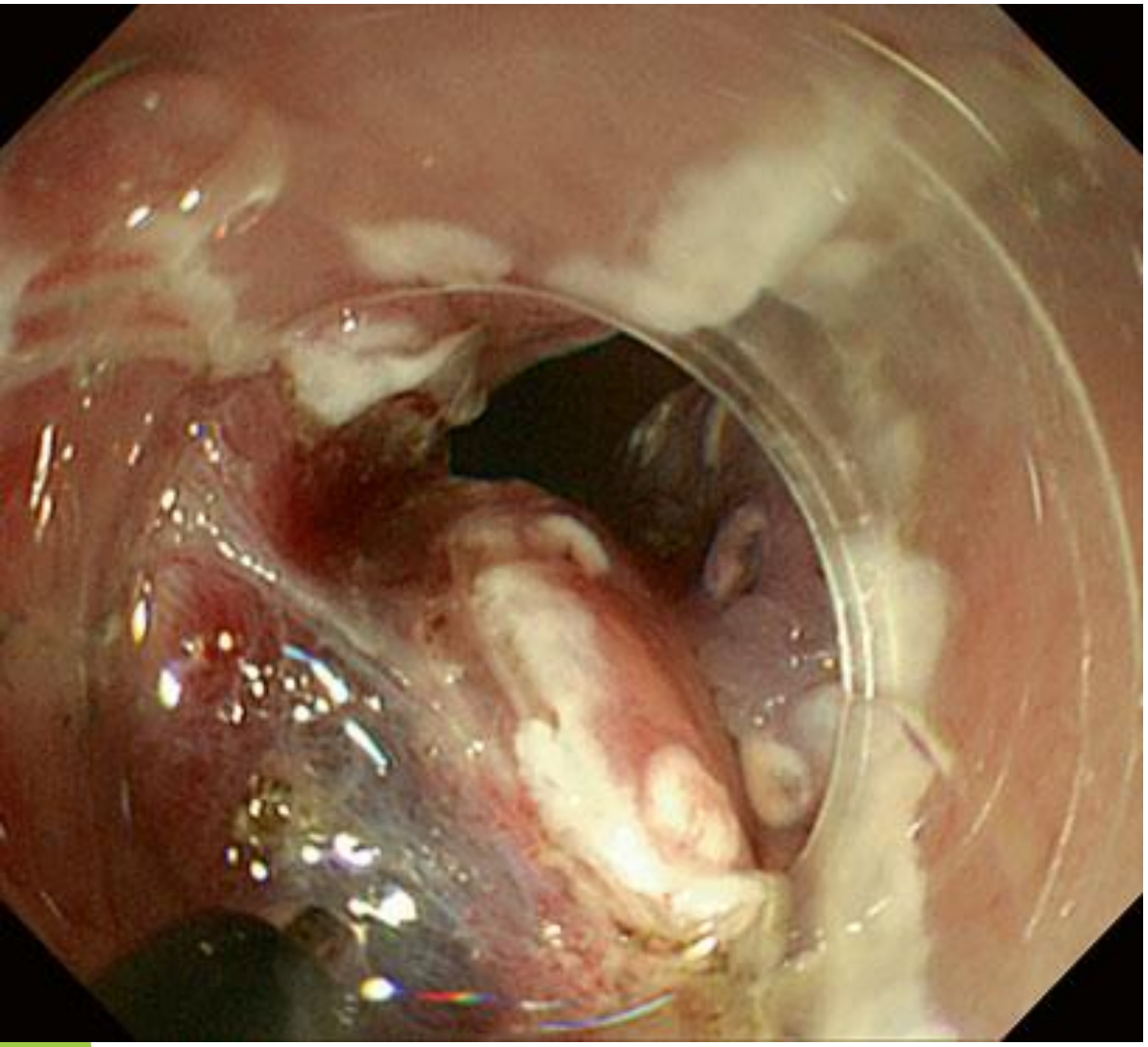

- The knife is inserted into the submucosal, and then the submucosal fibers are hooked and cut

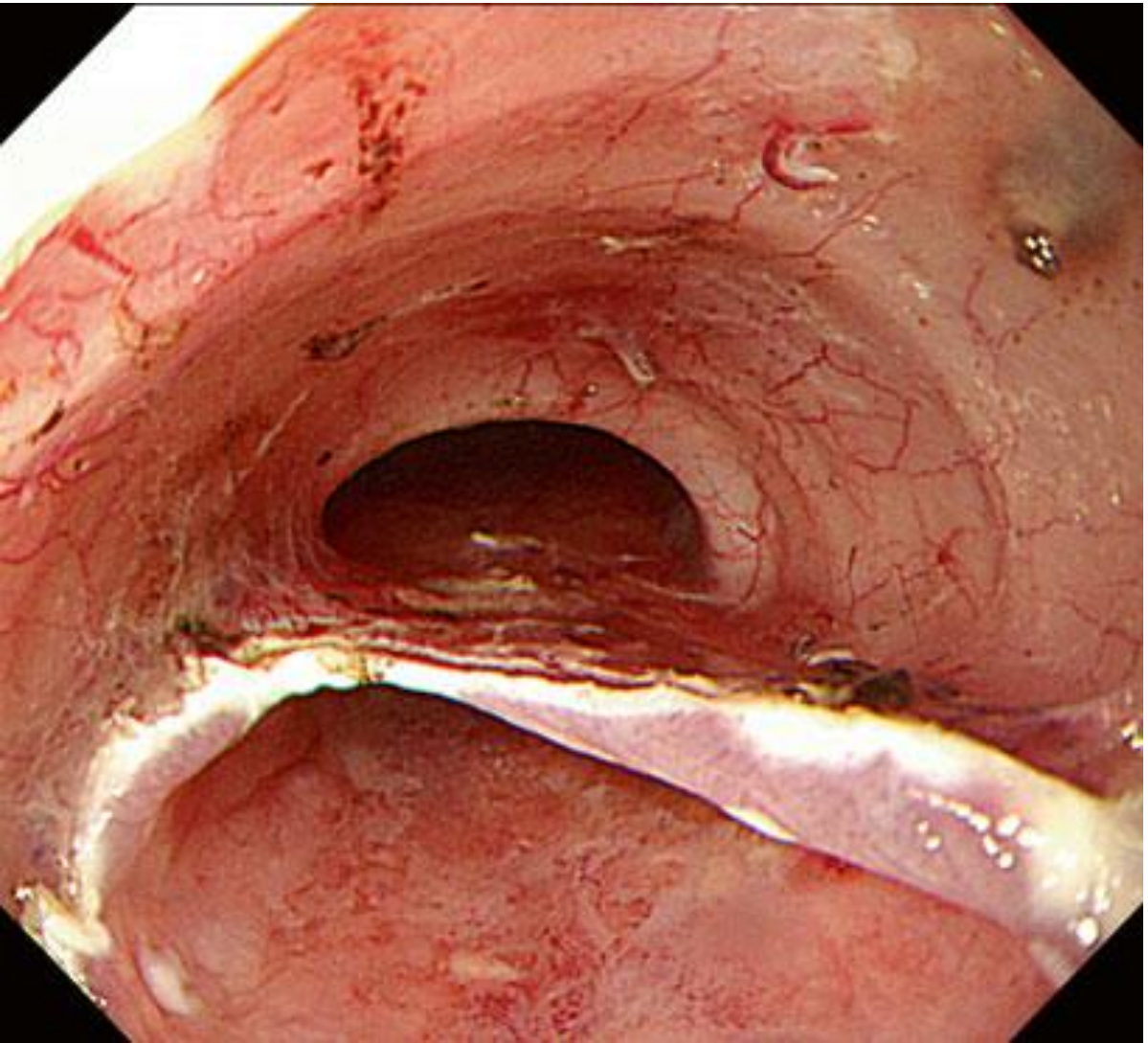

- After mucosal incision, a submucosal tunnel is made from the oral to anal side

Tunneling Method

- Tunnel-like dissection is necessary for circumferential ESD .
- At first, a circumferential mucosal incision of the anal and oral parts is performed
- After that, a mucosal tunnel is made from oral to anal, and the second tunnel is made at the opposite side.
- Finally, the remaining submucosal fibers are dissected between the two tunnels.

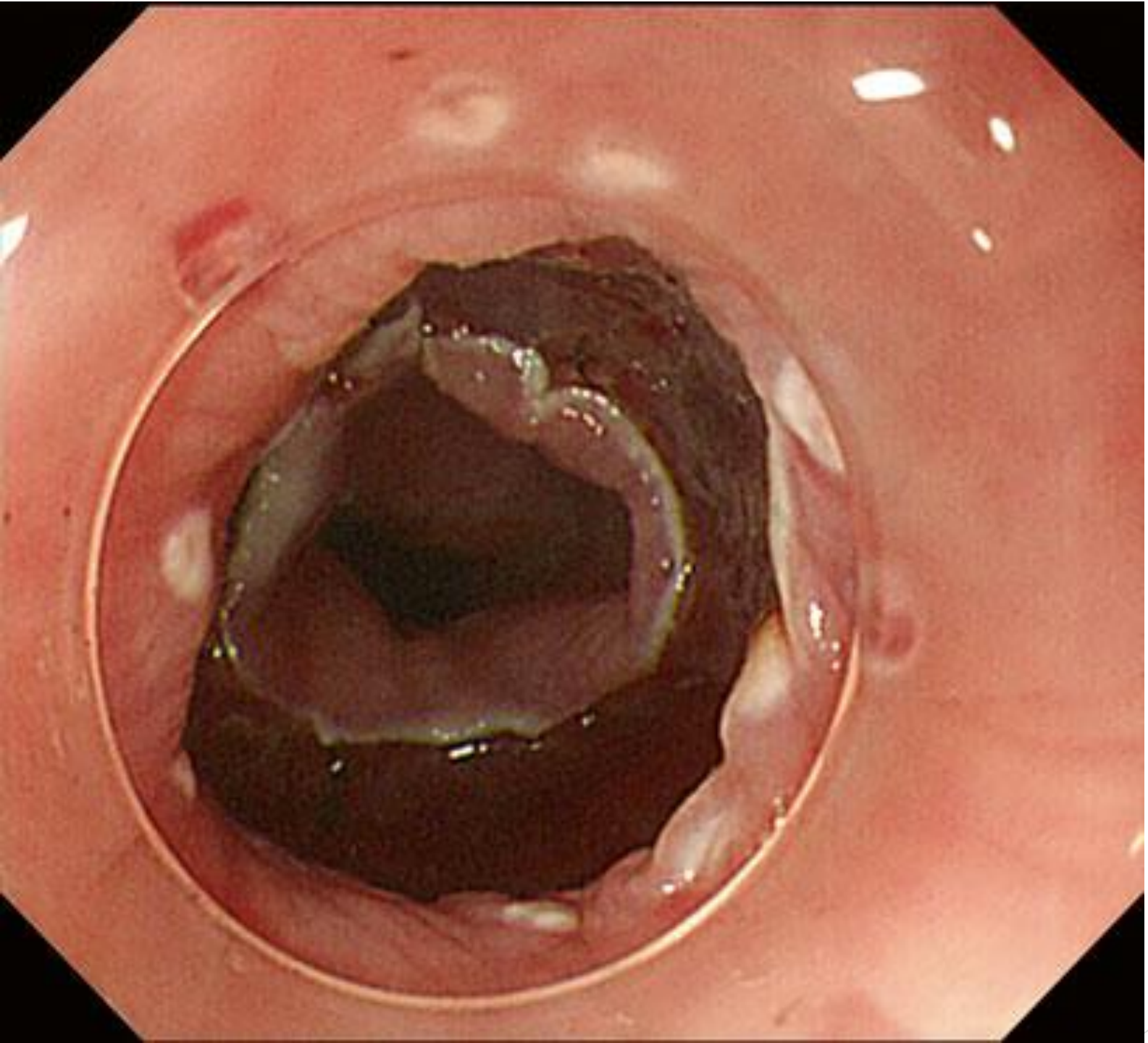

- Both oral and anal circumferential mucosal incisions were made

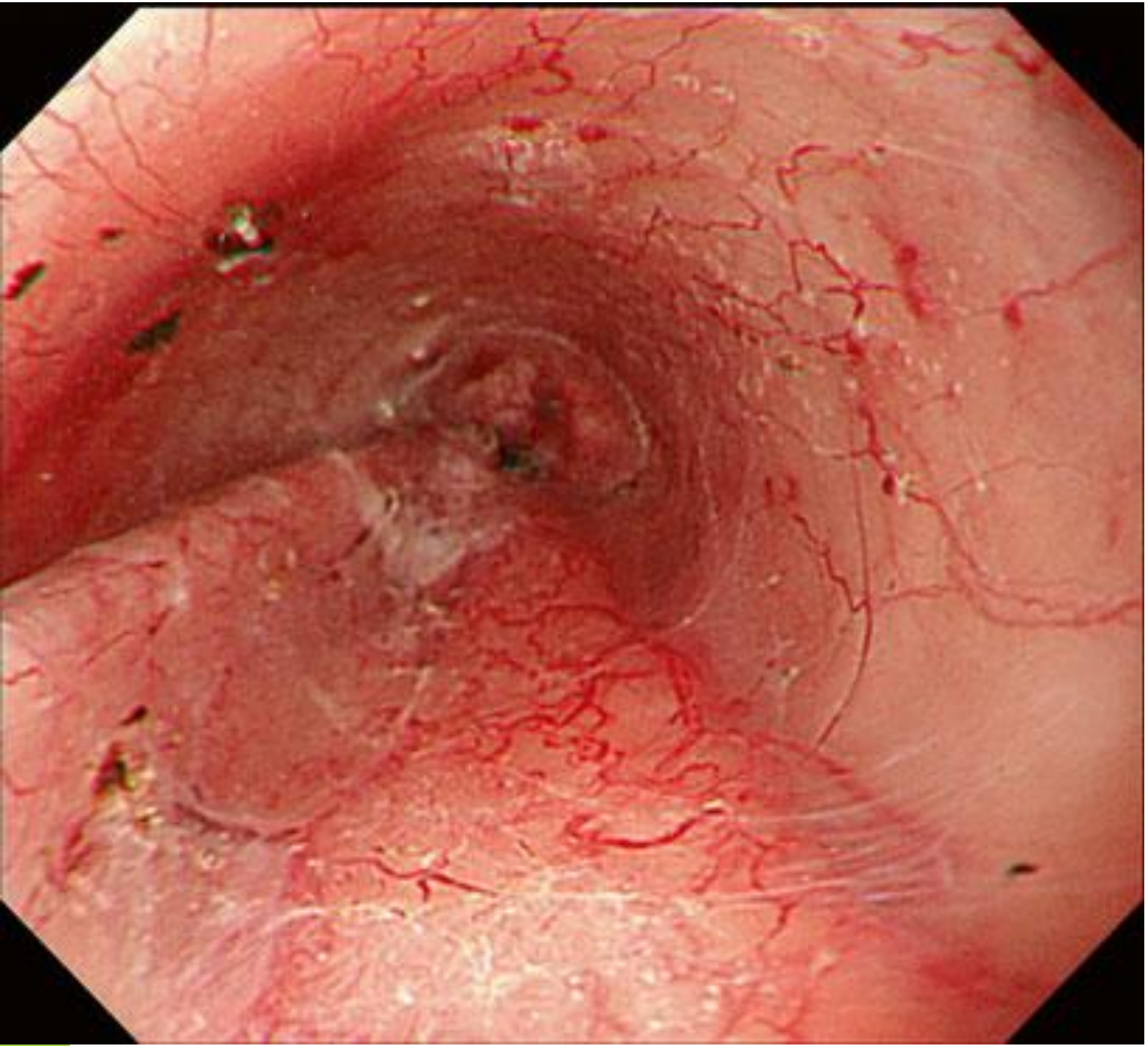

- At the opposite side, a second submucosal tunnel is made.
- The submucosal fibers remaining between the two tunnels are subsequently dissected

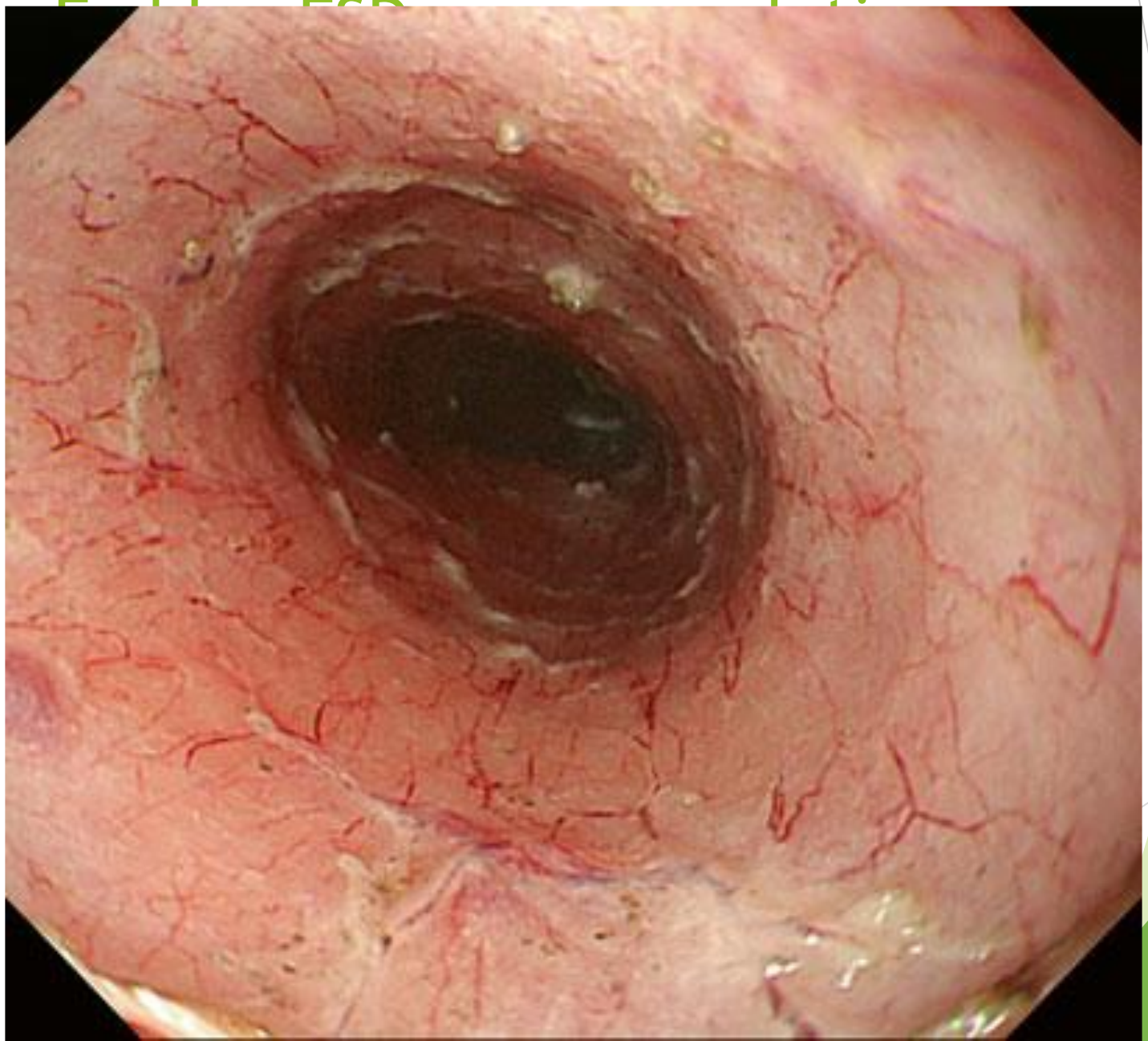

Clip-with-Line Method

- If you can pull the target lesion, good countertraction can be made.
- A long, 3-0, silk line is tied to the arm part of the clip Then the clip-with- line is reset in the cassette. The scope is withdrawn when the circumferential incision is finished. A clip applicator device is inserted into the accessory channel of the endoscope, and the clip-with-line is mounted onto the tip of the applicator. The scope is inserted again, and the submucosal side of the target lesion is grasped.
- After that, the line is pulled very gently. Only a small amount of tension is required to create countertraction. This method also creates a clear field of vision.
- During submucosal dissection, tension is maintained with a 10 g weight, such as a bite block mouthpiece, attached to the line. The 10 g weight creates sufficient countertraction and tension without threatening to tear the submucosal layer

Clip-with-line method

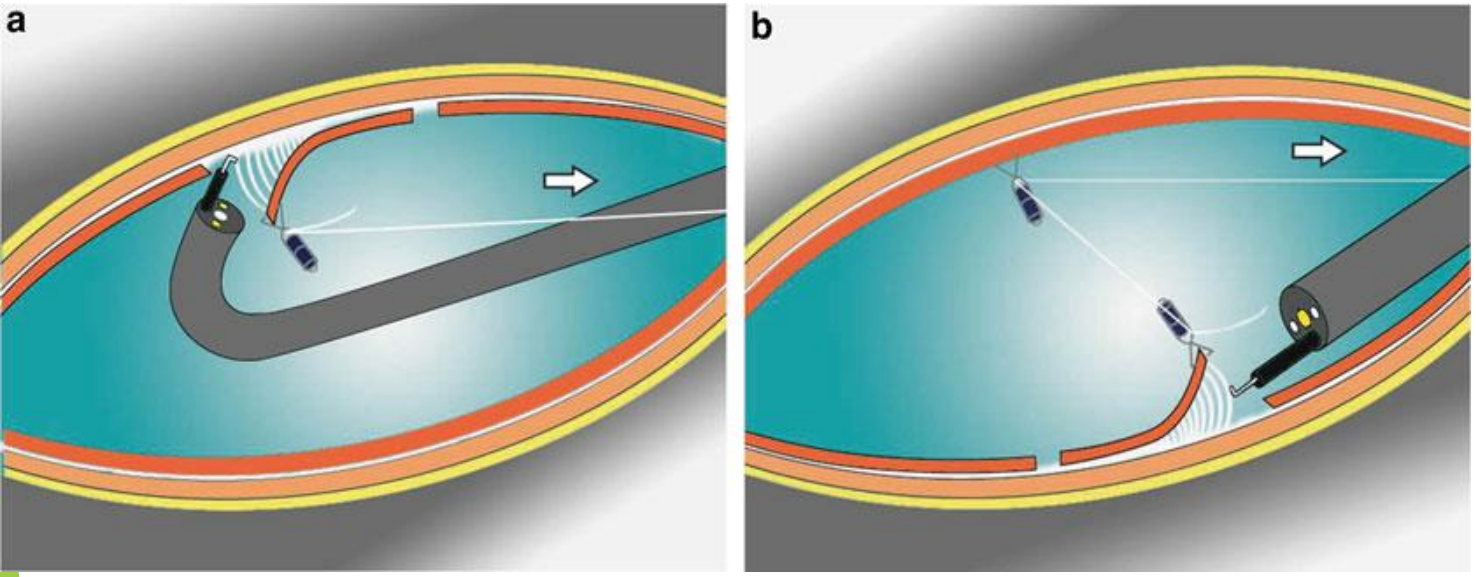

- (**a**) A clip is placed at the distal edge of the target lesion once circumferential mucosal incision is complete. Countertraction and a clear field of view are obtained by pulling very gently on the line.
- (**b**) A second clip can be used to change the direction of the countertraction.

A long silk line is attached to the arm part of a clip



The clip is used to grasp the submucosal side of the target lesion

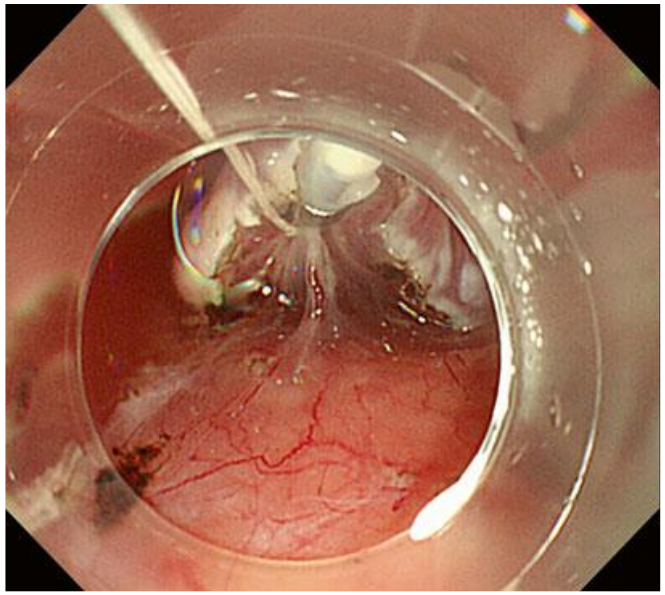

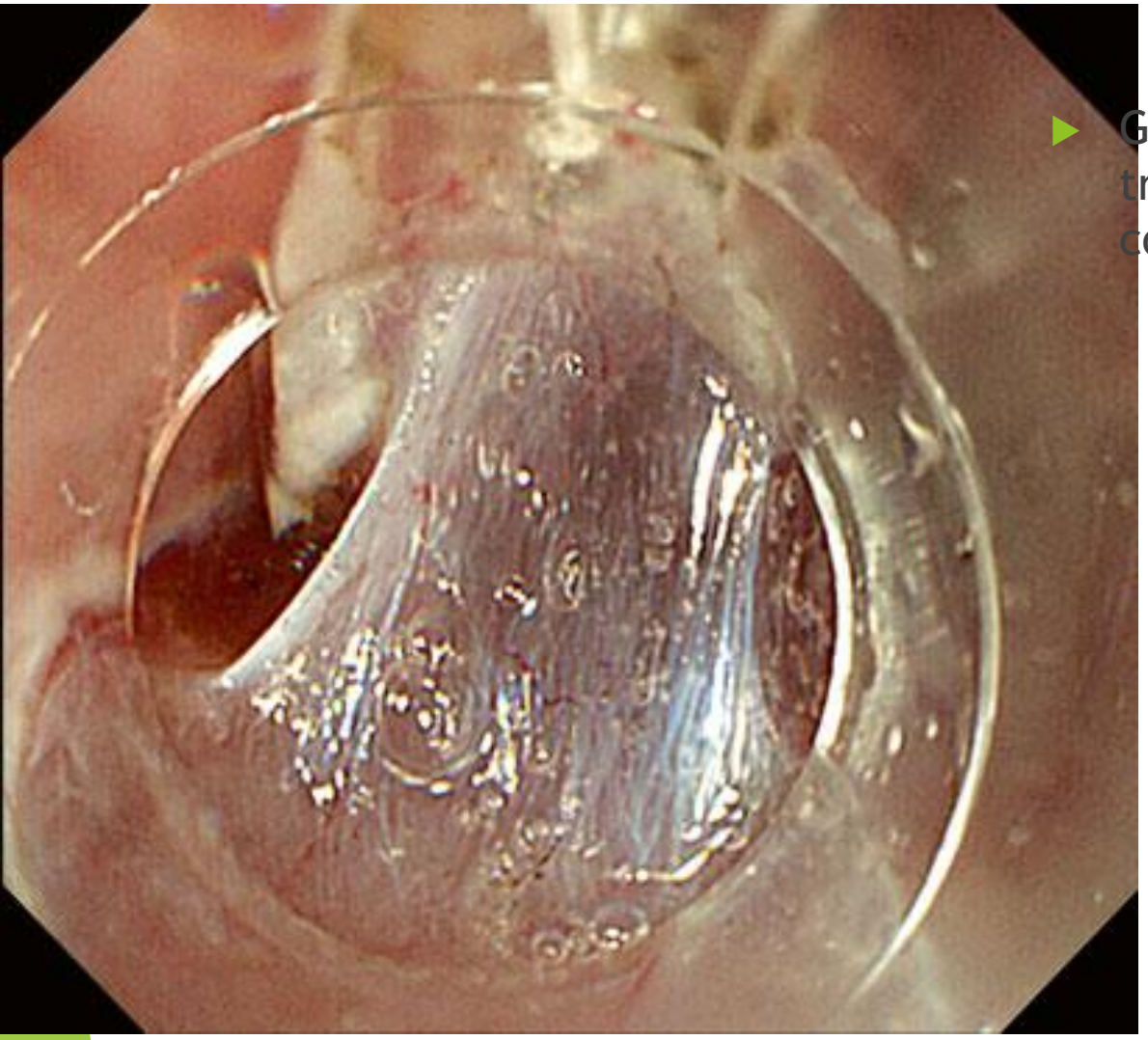

- Gentle pulling of the clip with traction line is used to provide countertraction

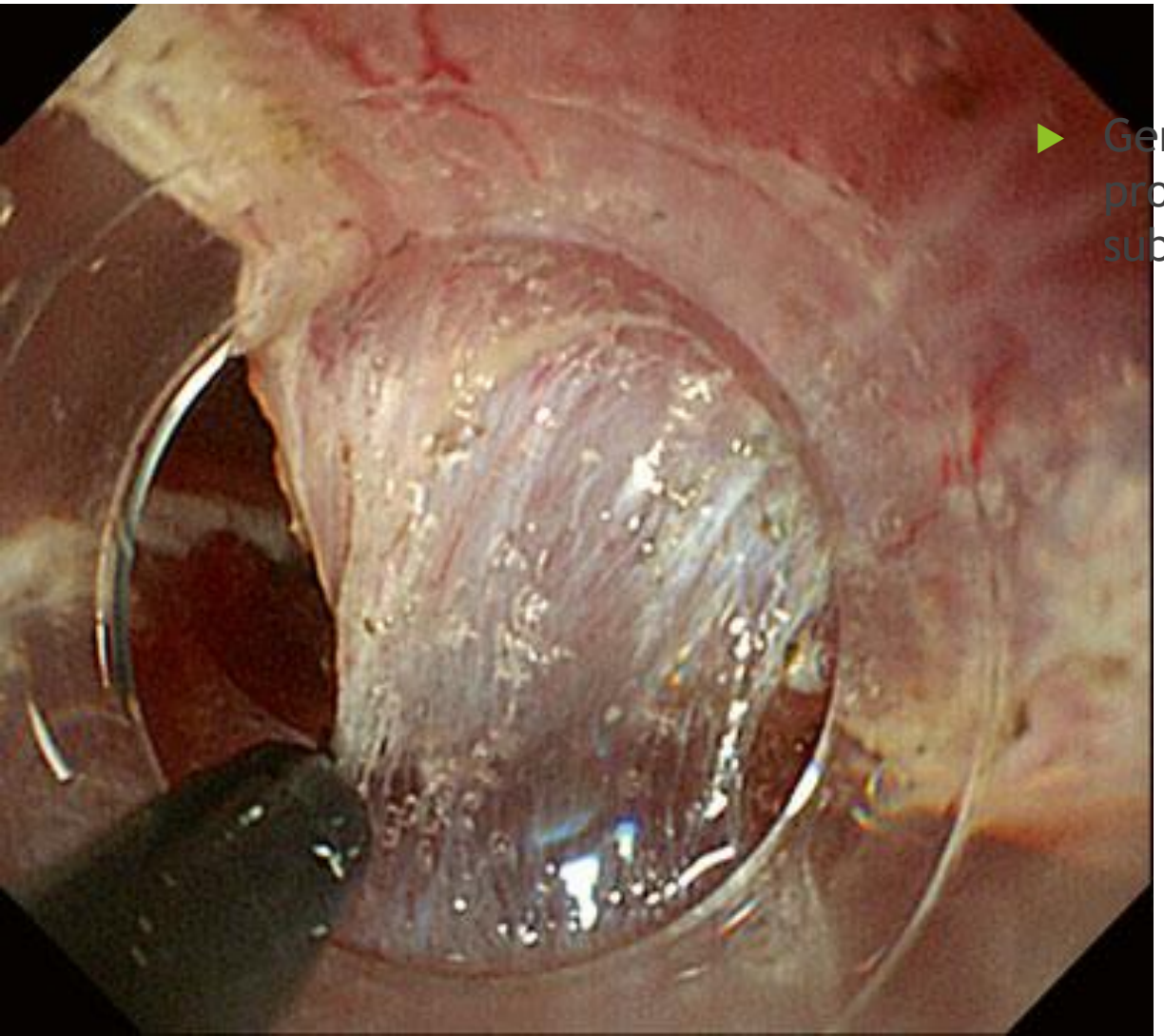

- Gentle pulling of the clip to provide countertraction facilitates submucosal dissection

Hemostasis

If a vessel is large (≥1 mm), precut coagulation to prevent bleeding should be performed

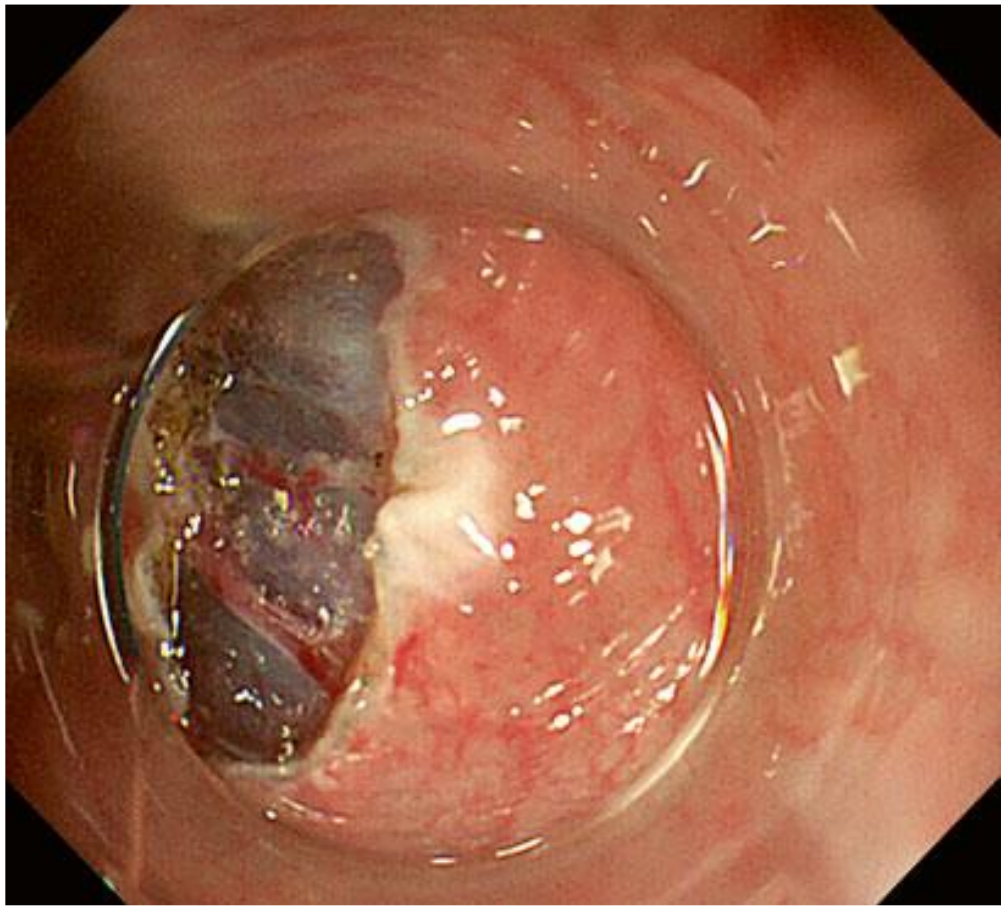

Hemostatic forceps are used to grasp the large vessel, and it is coagulated with soft coagulation (Effect 5, 60 W)

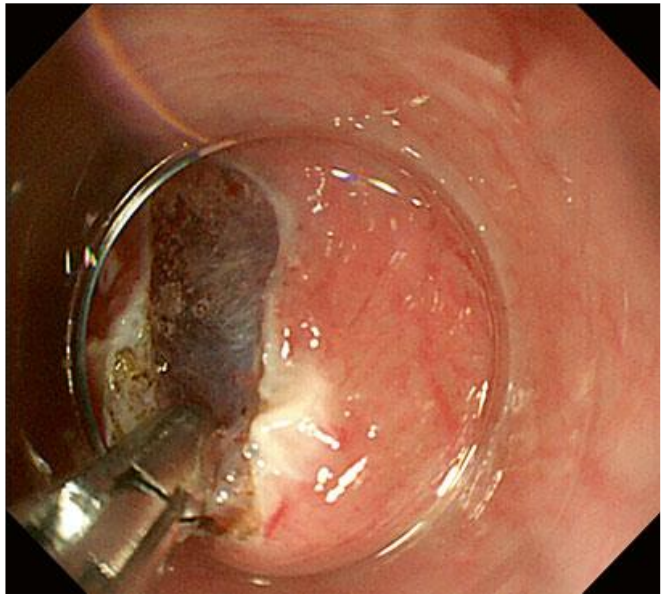

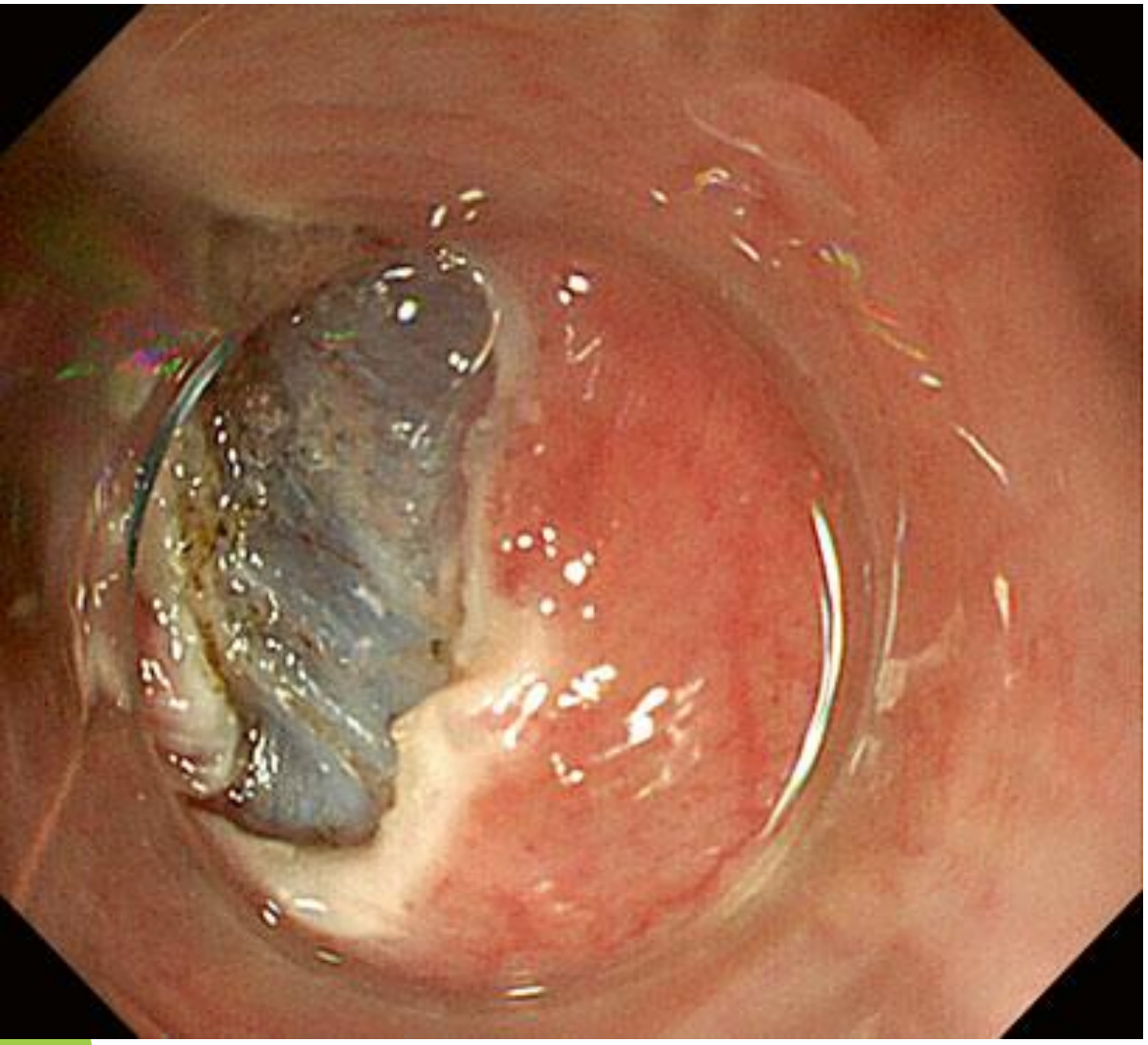

- The vessel can then be cut using the ESD knife and spray coagulation (Effect 2) without occurrence of any bleeding

ESD procedure for an erosive lesion in lower esophagus using IT knife

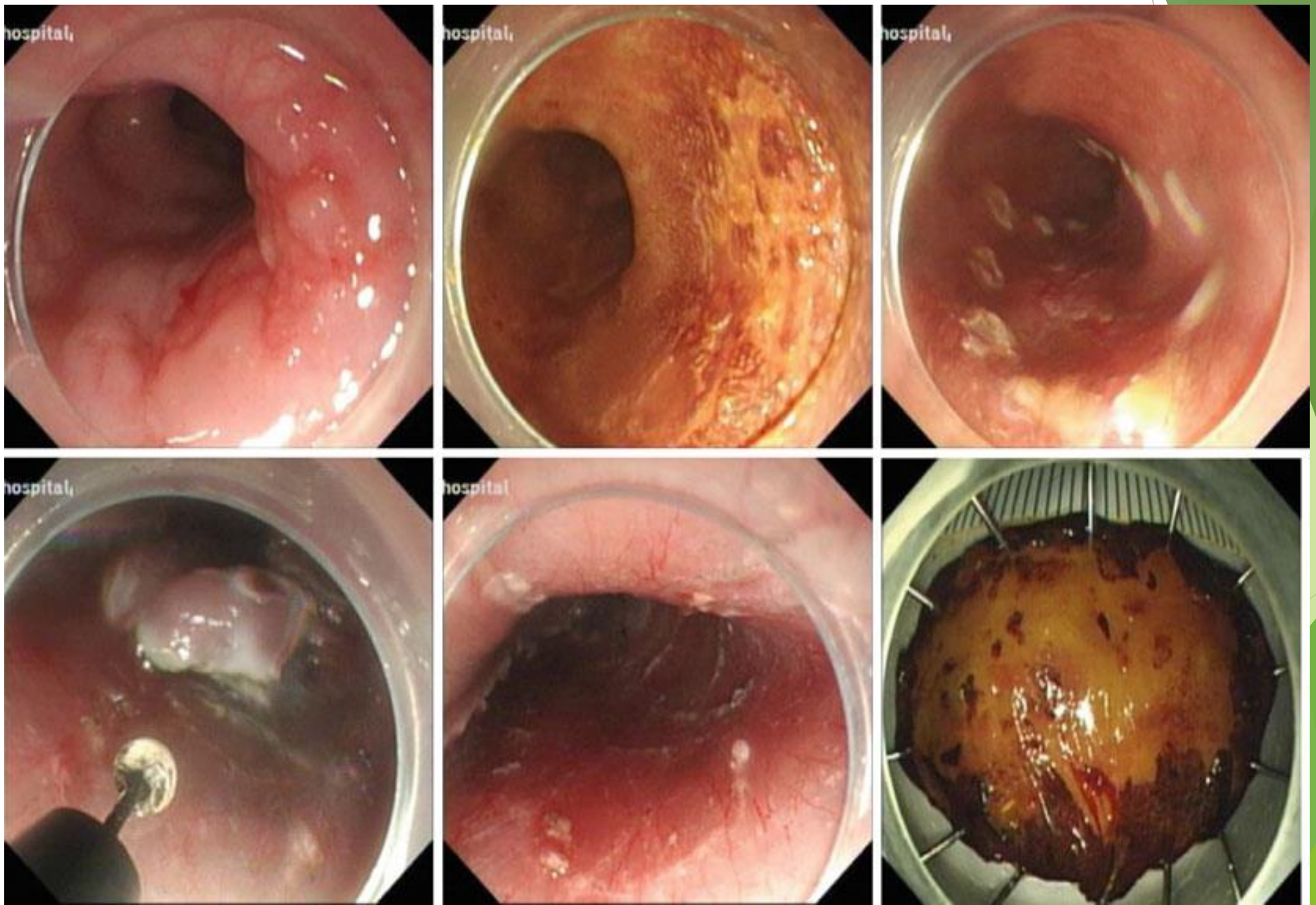

Postoperative Management and Follow-up

- Postoperative patients are observed for chest pain, dyspnea, cyanosis, abdominal pain or distention, and signs of peritonitis.
- If stable, patients allowed ***clear fluid the day after procedure*** and ***semi-solids from the day 2***.
- ***Regular diet is allowed 2 weeks after procedure***.
- Patients are prescribed ***PPI medication***.

- Follow-up endoscopy is scheduled at 1 month to ensure complete resection. Subsequent additional treatment is decided based on endoscopic and histopathological findings. Serial endoscopic examination is carried out at 3, 6, and 12 months and annually thereafter to check for recurrence.
- Patients at high risk of recurrence, such as with multifocal lesions receive 6-monthly endoscopic surveillance.
- Patients with high risk for nodal or distant metastasis, such as with ***m3 lesion***, also undergo annual CT imaging.
- ESD in esophagus is safe and effective but requires signifi cant expertise.

Complications
Bleeding

- Sometimes, the bleeding point during mucosal incision cannot be identified clearly due to the limited space, the lesion should then be dissected quickly and then successful hemostasis can be achieved afterwards using coagulation or clipping techniques

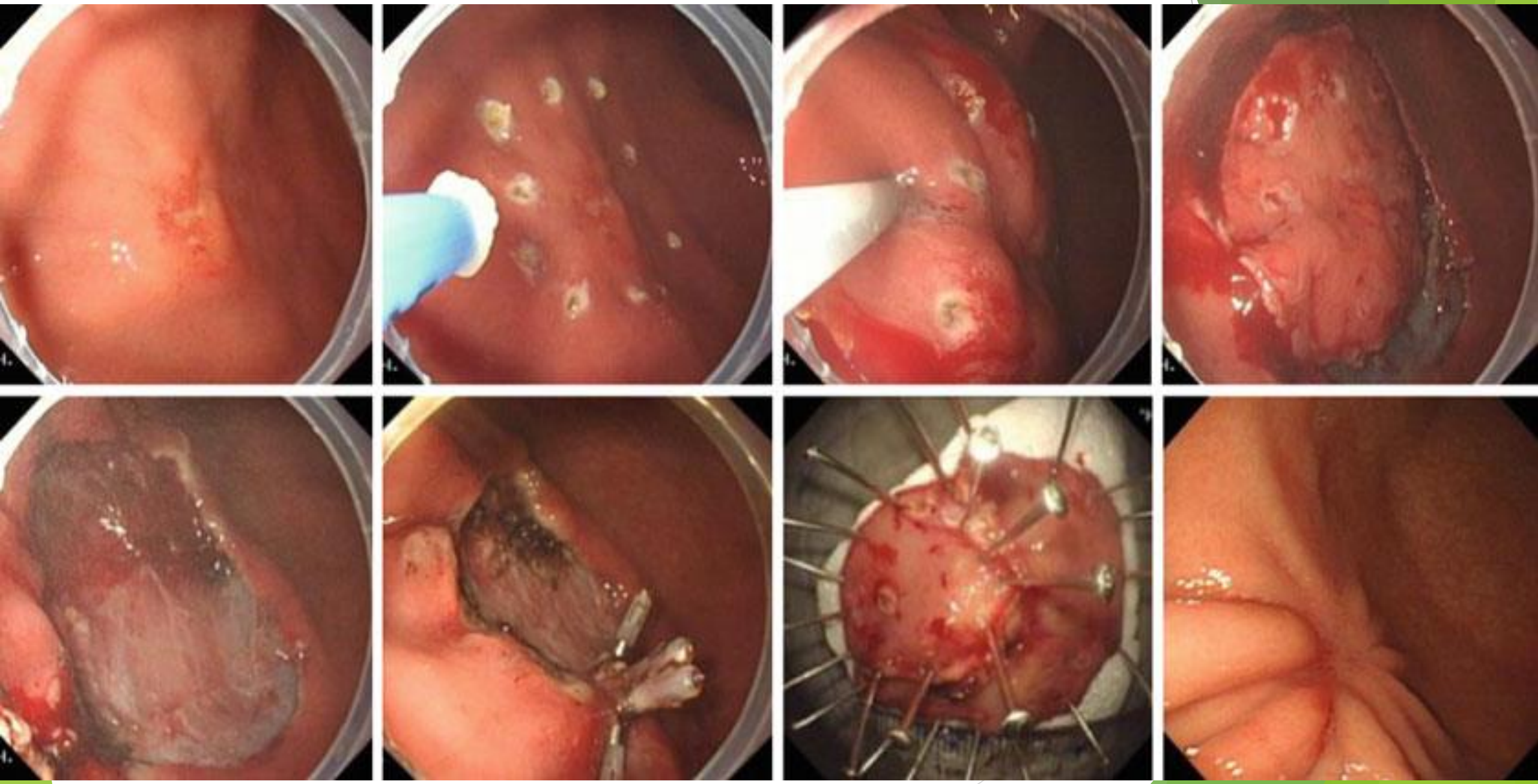

Delayed Bleeding

- within 0–30 days after the procedure
- 75% cases of postoperative bleeding occur within 24 h after ESD
- Important Factors:

1)Location of the lesion: ***cardia***

2)use of preventive methods for bleeding: Insufficient coagulation of visible vessels influences the likelihood of delayed bleeding

>>>>Pre-coagulate, Metal clips, PPI therapy, second-look endoscopy

3) size of the wound surface

Location of the lesion

- Excessive coagulation should be avoided to prevent delayed perforation, particularly in esophagus.
- Surgical option is considered if bleeding cannot be stopped.

Complications
Perforation

- The major complication of EMR/ESD is perforation, as well as air embolization and aspiration pneumonia.
- Perforations may cause ***mediastinal emphysema***, which increases the mediastinal pressure and crushes the esophageal lumen, leading to difficulty in securing the visual fi eld.
- Severe mediastinal emphysema may be complicated by ***pneumothorax***, which can lead to shock; therefore, electrocardiography, arterial oxygen saturation, and blood pressure (using an automated sphygmomanometer) monitoring should be conducted during ESD, as well as periodic observation for subcutaneous emphysema through palpation.

- CO2 insufflation is useful for preventing such severe mediastinal emphysema. Since the esophagus has no serous membrane and the intramediastinal pressure is lower than that of the esophageal lumen, ***mediastinal emphysema may occur in the absence of perforation***. Dissection immediately above the proper muscular layer may damage the proper muscular layer during electrical discharge, which often causes mediastinal emphysema.

- It is important to dissect the submucosal layer making sure to leave the lowest one-third without any exposure of the proper muscular layer. Under intubation general anesthesia, the mediastinal pressure is higher than the intraesophageal pressure, enabling prevention of mediastinal emphysema and/or subcutaneous emphysema.
- Therefore, ***intubation general anesthesia*** is preferable form large lesions that are expected to take two or more hours for complete resection.

- The perforation rate caused by esophageal EMR has been reported as 0–2.4 %, and that of ESD as 0–6.4 %.
- ***The shape and size of perforation caused by EMR is different from that caused by ESD***. Muscle removed by EMR can be up to 1 cm or larger, and sometimes closure by clips is diffi cult. On the other hand, the shape of perforation caused by ESD is linear, without defect of proper muscle, and so closure by clips is usually easier than that of EMR.
- ***Sometimes the clip may injure the remaining proper muscle and make the perforation larger***.
- ***The operator should be skilled at clipping***. Usually such perforations can be treated by fast insertion of a nasoesophageal tube and intravenous antibiotic administration, without need for surgery.

- Water jets are useful for the detection of the bleeding point. However, sometimes water refl ux causes aspiration pneumonia.
- A flexible overtube is a useful device for prevention of aspiration pneumonia.
- General anesthesia with tracheal intubation is necessary for the cervical esophageal ESD because the risk of aspiration pneumonia is high.

Stricture

- Stricture is a major complication after ESD.
- A mucosal defect of more than three-quarters of the circumference is a reliable predictor of stricture.
- Post-ESD stricture substantially decreases a patients' quality of life and requires multiple endoscopic balloon dilation (EBD) sessions.
- Preventive EBD has been the treatment of choice to prevent stricture; however, even after six sessions of preventive EBD, stricture is a frequent complication.

- Efficacy of ***prophylactic oral prednisolone*** for prevention of post-ESD stricture was described.
- Reduced the stricture rate
- The cumulative dose of prednisolone was approximately 1,000 mg, and exposure to such a high prednisolone dose raises concerns regarding adverse effects.
- The efficacy of ***intralesional triamcinolone injection*** to prevent stricture after esophageal ESD has also been described.
- Especially worth noting is research by Hanaoka et al., where the effect of ***a single session of intralesional steroid injections immediately after ESD*** was studied. In this prospective study they compared the results with a historical control group of patients who underwent ESD without intralesional steroid injection. The treatment group had a signifi cantly lower stricture rate (10 %, 3/30 patients vs. 66 %, 19/29 patients; $p < 0.0001$) and a lower number of EBD sessions (median 0, range 0–2 vs. median 2, range 0–15; $p < 0.0001$).

A novel, unique method

- ***Specimens of oral mucosal tissue*** were collected from nine patients with superficial esophageal neoplasms.
- ***Epithelial cell sheets*** were fabricated ex vivo by culturing isolated cells for 16 days on temperature-responsive cell culture surfaces.
- After a reduction in temperature, these sheets were endoscopically transplanted directly to the ulcer surfaces of patients who had just undergone ESD.
- Complete re-epithelialization occurred ***within a median time of 3.5 weeks***. No patients experienced dysphagia, stricture, or other complications following the procedure, except for one patient who had a full circumferential ulceration that expanded to the esophagogastric junction